SPINE Volume 32, Number 14, pp 1555–1560


# Does Lumbar Facet Fluid Detected on Magnetic Resonance Imaging Correlate With Radiographic Instability in Patients With Degenerative Lumbar Disease?

Jeffrey A. Rihn, MD,* Joon Y. Lee, MD,* Mustafa Khan, MD,* James A. Ulibarri, MD,* Chadi Tannoury, MD,† William F. Donaldson, III, MD,* and James D. Kang, MD*

**Study Design.** Retrospective radiographic/imaging study.

**Objective.** The purpose of this study was to analyze the association between lumbar facet fluid on MRI and sagittal instability on flexion lumbar radiographs in patients with degenerative disease at L4–L5. We hypothesized that the amount of facet fluid on MRI correlates with instability on the flexion radiograph.

**Summary of Background Data.** Although never formally studied, it has been suggested that lumbar facet fluid detected on MRI is indicative of spinal segment instability.

**Methods.** Patients who underwent laminectomy or laminectomy and fusion for the treatment of degenerative lumbar disease at L4–L5 at our institution between 2002 and 2004 and who had preoperative lumbar MRI and anteroposterior and flexion-extension radiographs available for review were study eligible. Axial T2 MRI images through the L4–L5 facets were analyzed for facet fluid. The facet fluid index was calculated, *i.e.,* the ratio of the sum of the width of fluid in each facet (bilateral) to the sum of the width of each facet (bilateral). Instability on the flexion radiograph was measured as percent anterior slip at L4–L5.

**Results.** Fifty-one patients were included in the study, 28 (55%) of whom had facet fluid noted on MRI. Of those patients who did have facet fluid on the MRI, 23 of 28 had instability on the flexion lumbar radiograph and 5 of 28 had no instability. The mean facet fluid index and percent anterior slip for the 28 patients with MRI facet fluid was 0.12% and 11.1%, respectively. There was a positive linear association between these values (Pearson correlation coefficient of 0.90, $P < 0.001$). The positive predictive value of L4–L5 facet fluid on MRI as an indicator of radiographic instability was 82%.

**Conclusions.** There is a close linear association between the facet fluid index and the amount of radiographic instability at L4–L5. Facet fluid on MRI should raise high suspicion of lumbar instability.

**Key words:** degenerative, lumbar, facet, fluid, MRI, instability. **Spine 2007;32:1555–1560**

From the *Department of Orthopaedic Surgery, University of Pittsburgh School of Medicine, Pittsburgh, PA; and the †Department of Orthopaedic Surgery, Thomas Jefferson University, Philadelphia, PA.
Acknowledgment date: June 8, 2006. First revision date: September 6, 2006. Second revision date: November 15, 2006. Third revision date: December 4, 2006. Acceptance date: December 5, 2006.
The manuscript submitted does not contain information about medical device(s)/drug(s).
No funds were received in support of this work. No benefits in any form have been or will be received from a commercial party related directly or indirectly to the subject of this manuscript.
Address correspondence and reprint requests to Joon Y. Lee, MD, University of Pittsburgh School of Medicine, Department of Orthopaedic Surgery, 3741 Fifth Avenue, Suite 1010, Pittsburgh, PA 15213; E-mail: jrihno16@yahoo.com

Whether an arthrodesis is performed in addition to a laminectomy for symptomatic lumbar stenosis may depend on the stability of the involved spinal segments. Several studies support arthrodesis at the time of laminectomy in those patients with evidence of degenerative spondylolisthesis.[1–3] For this reason, it is important to accurately identify those patients who have lumbar spine segmental instability in addition to spinal stenosis. Traditionally, spinal instability has been evaluated using weight-bearing lateral flexion-extension radiographs, where anteroposterior (AP) translation is suggestive of lumbar spine instability.[4–7] Although contradictions exist in the literature, several studies support the use of these dynamic radiographs.[4–6,8] Other imaging methods, including traction-compression radiographs,[9] dynamic magnetic resonance imaging (MRI),[10–12] and three-dimensional dynamic computed tomography,[13] have been reported as useful means of evaluating the lumbar spine for instability. There is currently no consensus in the literature, however, on the most reliable means of accurately diagnosing lumbar instability.

Several studies have found that degeneration of the lumbar facet joints is coupled to intervertebral disc degeneration, both of which are important contributors to instability.[14–22] It has been suggested that fluid collection within the lumbar facet detected on MRI is indicative of segmental instability.[23] Mailleux *et al*[23] reported 2 cases of degenerative lumbar spondylolisthesis with stenosis, which was not initially detected using MRI due to reduction of the spondylolisthesis in the supine position. Facet fluid was detected on the MRI at the involved lumbar segments. Although this case report suggests that facet fluid detected on MRI should raise suspicion of lumbar instability, this issue has not, to our knowledge, been formally studied.

MRI is commonly used to evaluate patients with degenerative lumbar disease and lumbar spinal stenosis. The signs of lumbar intervertebral disc degeneration on MRI are well described in the literature.[24,25] Several studies have attempted to characterize the association between intervertebral disc degeneration on MRI and lumbar spinal segmental instability with inconsistent results.[21,26,27] Less has been published regarding the MRI evaluation of lumbar facet degeneration.[21,28] Recently, Fujiwara *et al* studied the association between intervertebral disc and facet joint degeneration and developed an MRI-based grading system for the severity facet joint degeneration.[22] These authors found that both interver-

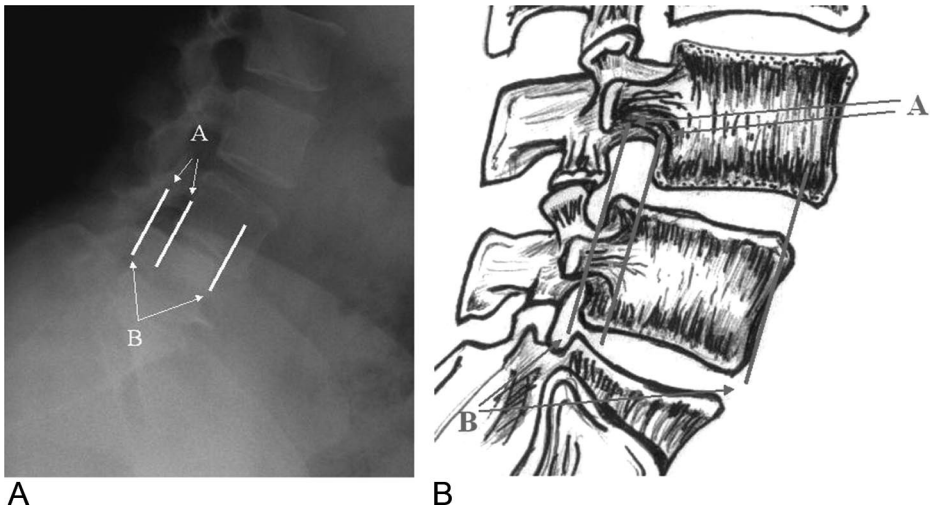


Figure 1. (**A**) Lateral weight-bearing flexion radiograph and (**B**) an illustration of the lumbar spine demonstrating the measurement of spondylolisthesis. The percentage of anterior slip of L4 on L5 was calculated as follows: (A/B) × 100.

tebral disc and facet degeneration correlated positively with segmental instability of the lumbar spine.[22] Additional MRI studies have evaluated facet joint orientation and tropism and found that increased sagittal lumbar facet orientation and greater facet tropism correlate to increased intervertebral disc degeneration and the presence of degenerative spondylolisthesis.[29–32]

Fluid within the facet is the result of degeneration of the synovial facet joint. Like fluid in other arthritic synovial joints (*i.e.*, knee, shoulder, hip), facet fluid is readily detectable using MRI. In contrast to T1-weighted MRI sequences (*i.e.*, "fat sequences"), which are excellent for defining normal anatomy, T2-weighted MRI sequences display extracellular free water as a bright signal intensity. For this reason, the T2-weighted sequences are most helpful when looking for facet fluid. It is logical, based on previous biomechanical studies that demonstrate the importance of facet integrity in lumbar spinal stability, that a lumbar spinal segment with degenerative, fluid-filled facets would demonstrate instability. The association between facet fluid detected on MRI and radiographic lumbar instability, however, has not been investigated.

The purpose of this study was to analyze the association between lumbar facet fluid detected on MRI and sagittal instability detected on lateral flexion lumbar radiographs in patients with degenerative lumbar disease. We hypothesize that the amount of facet fluid detected on MRI will have a positive correlation to the amount of sagittal instability detected on the lateral flexion radiograph.

## ■ Materials and Methods

After obtaining Institutional Review Board approval, all patients with degenerative lumbar disease who underwent laminectomy and arthrodesis or laminectomy alone at L4–L5 between the years 2002 to 2004 were reviewed to determine study eligibility. Only those patients with a preoperative MRI and preoperative AP and weight-bearing flexion-extension lateral lumbar radiographs available for review were included in the study. Patients who had previous lumbar surgery and patients with an etiology for lumbar disease other than degenerative (*i.e.*, trauma, infection, tumor) were excluded from the study. Patients with evidence of adjacent level degenerative disease on the radiographs and/or MRI were not excluded.

Using the above criteria, 53 patients with degenerative lumbar disc disease at L4–L5 were identified. In this study, instability was defined as the presence of anterior translation of L4 on L5 in the sagittal plane, as determined on the lateral flexion lumbar radiograph. The percentage slip of L4 on L5 was calculated on the flexion radiograph by measuring the amount of anterior slip of L4 on L5 (using the posterior cortices of the L4 and L5 vertebrae as references), dividing this value by the sagittal width of the superior endplate of the L5 vertebra, and multiplying this number by 100 (Figure 1). The AP radiograph was evaluated for evidence of coronal plane translation at L4–L5. No patients, however, had evidence of lateral listhesis of L4 on L5 on the AP radiograph. Therefore, radiographic translation in the coronal plane was not included in our definition of radiographic instability.

Axial T2-weighted MRI sequences through the L4–L5 facet were analyzed for the presence of facet fluid. Fluid within the facet joints was characterized by an increased signal on the T2-weighted sequence (Figure 2). The facet fluid index for L4–L5 was calculated at the widest cross-sectional facet area on the axial MRI. This index is defined as the ratio of the sum of the width of fluid in each facet (bilateral) to the sum of the width of both of the facets (bilateral). Facet measurements (*i.e.*, facet width and width of facet fluid) were made in line with facet orientation on the axial MRI section (*i.e.*, approximately 45° from the floor) (Figure 3). All measurements (radiographic and MRI) were taken by an independent examiner who was not directly involved with the care or surgery of the patients and repeated by an additional independent examiner to allow for calculation of interobserver reliability. All measurements were repeated 1 month after the initial set of measurements was taken to allow for calculation of intraobserver reliability. All measurements were taken digitally with magnification, using the measurement tool function of Adobe Photoshop (San Jose CA, 2005).

**Statistical Methods.** All data were entered into a computerized database. Statistical analyses were performed with SPSS, version 12.0.1, for a personal computer (SPSS Inc., Chicago, IL). Descriptive statistics were calculated, including frequencies

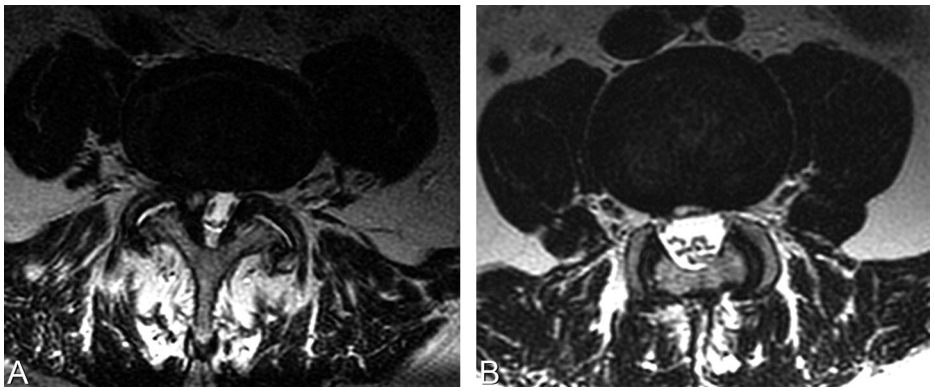


Figure 2. **A**, T2 axial MRI image at the level of the L4–L5 facet joints in a patient with lumbar stenosis and degenerative spondylolisthesis at L4–L5. Increased signal within the facets bilaterally indicates the presence of facet fluid. **B**, For comparison, a T2 axial MRI image at the level of the L4–L5 facet joints in a patient with no evidence of facet fluid.

for categorical and ordinal variables and means, medians, standard deviations, and ranges for continuous variables. Pearson's correlation coefficient was calculated to analyze the association between the facet fluid index and the slip percentage. Significance was set at a $P$ value of $<0.05$. Odds ratios were calculated using a confidence interval (CI) of 95%.

In order to assess interobserver reliability, the intraclass correlation coefficient was calculated using the measurements taken by the two independent examiners for both the facet fluid index and the percent of radiographic slip of L4 on L5. In order to assess the intraobserver reliability, the intraclass correlation coefficient was calculated using the initial and repeated (1 month after initial) measurements of the facet fluid index and the percent of radiographic slip of L4 on L5. The intraclass correlation coefficient can range from 0 to 1, with a value of 1 representing perfect agreement between examiners. A value of less than 0.4 is considered poor reliability; from 0.4 to 0.75 fair reliability; and $>0.75$ excellent reliability.[33] For calculation of the intraclass correlation coefficients, we used a two-way mixed model and a CI of 95%.

## Results

At total of 53 patients were included in the study based on the study criteria. Two of these patients, however, were subsequently excluded from the study because they had facet fractures noted on MRI. There were 23 (45.1%) males and 28 (54.9%) females, with an average age of 60 years (range, 30–88 years).

When looking at all 51 study patients, 23 (45%) patients had no facet fluid present on MRI and 28 (55%) did have facet fluid noted on MRI. Of those patients with no facet fluid on MRI, 4 of 23 had instability noted on the flexion lumbar radiograph and 19 of 23 had no instability noted. Of those patients who did have facet fluid on the MRI, 23 of 28 had instability noted on the flexion lumbar radiograph and 5 of 28 had no instability noted. These results are summarized in Table 1.

In regards to the 28 patients who did have facet fluid present on the MRI, the mean facet fluid index and percent anterior slip of L4 on L5 was 0.12 (range, 0.04–0.36) and 11.1% (range, 0%–30%), respectively. There was a significant positive linear correlation between the facet fluid index and the percent radiographic slip, with a Pearson correlation coefficient of 0.9 and an $R^2$ value of 0.82 ($P < 0.01$) (Figure 4). The calculated positive predictive value and negative predictive value when using the presence of L4–L5 facet fluid on MRI as an indicator of radiographic lumbar instability was 82% and 83%, respectively. Patients with facet fluid had far greater likelihood of having instability than those without facet fluid (odds ratio = 21.9; 95% CI, 5.1–93.0). The intraclass correlation coefficients for the facet fluid index and the percentage of radiographic slip measured by two independent observers were 0.91 (95% CI, 0.79–0.97) and 0.90 (95% CI, 0.76–0.96), respectively. The intraclass correlation coefficients calculated using the initial and repeated measurements of the facet fluid index and the percent of radiographic slip of L4 on L5 were 0.94 (95% CI, 0.86–0.98) and 0.96 (95% CI, 0.91–0.99).

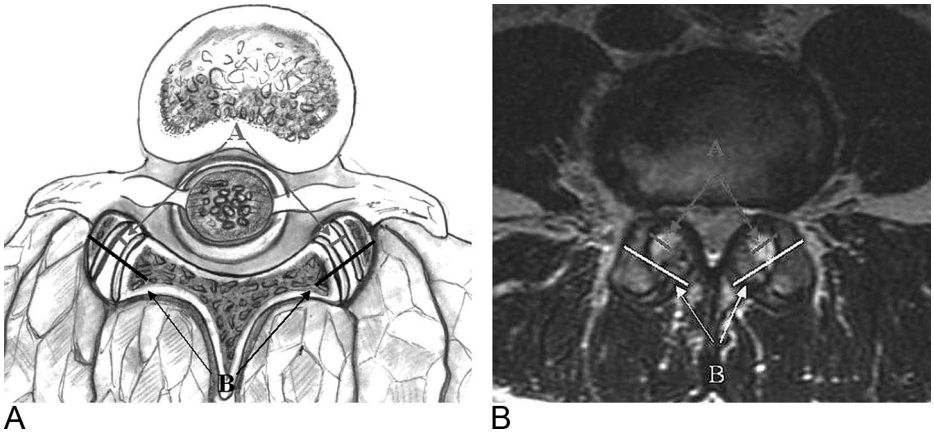


Figure 3. An (**A**) illustration and (**B**) T2 axial MRI image of the lumbar spine demonstrating the measurement of the facet fluid index. The facet fluid index is calculated at the widest cross-sectional facet area on the axial MRI. Facet fluid index is defined as the sum of facet fluid width (**A** arrows) divided by the sum of facet width (**B** arrows).

**Table 1. Summary of Data That Compare the Presence of Facet Fluid on MRI to the Presence of Radiographic Instability**

| | Radiographic Instability* | No Radiographic Instability* |
|---|---|---|
| Facet fluid on MRI | 23 (TP) | 5 (FP) |
| No facet fluid on MRI | 4 (FN) | 19 (TN) |

TP, true positive; FP, false positive; TN, true negative; FN, false negative. Values are used to calculate positive predictive value and negative predictive value.
*Radiographic instability is defined in this study as the presence of anterior translation of L4 on L5 in the sagittal plane, as determined on the lateral flexion lumbar radiograph. This does not account for translational or rotational instability, neither of which was formally measured as part of this study. It is possible that some study patients may have had translational or rotational instability that was not detected on the lateral flexion lumbar radiograph.

## Discussion

We have shown in this study that a close linear association exists between the amount of lumbar facet fluid present on MRI (*i.e.*, facet fluid index) and the amount of anterior instability detected on the lateral flexion lumbar radiograph. The presence of facet fluid is indicative of radiographic lumbar instability with a relatively high positive predictive value (82%). Our data also suggest that both the facet fluid index and the amount of radiographic lumbar instability can be calculated with high interobserver and intraobserver reliability. In light of these findings, the presence of facet fluid on MRI should raise high suspicion of lumbar instability. Our data also suggest, however, that MRI alone should not be used to diagnose lumbar instability, as 15% of patients with radiographic evidence of instability did not have facet fluid present on the MRI. Furthermore, 19% of patients with facet fluid on MRI had no radiographic evidence of instability. Given this information, weight-bearing flexion-extension radiographs remain essential for complete evaluation of lumbar instability.

The biomechanics and pathophysiology of degenerative lumbar disease are complicated and not fully understood. The facet joints are typical diarthrodial joints, consisting of a joint capsule and hyaline articular cartilage overlying the subchondral bone of the inferior articular process of the cephalad vertebra and the superior articular process of the caudal vertebra. They undergo the same process of degeneration that is seen in other synovial joints with osteoarthritis. This process involves deterioration of cartilage, subchondral sclerosis, osteophyte formation, and accumulation of fluid within the joint.

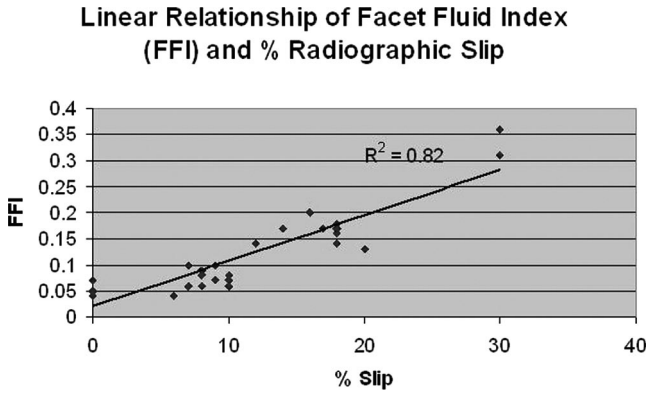


Figure 4. Correlation between the facet fluid index and degree of spondylolisthesis.

The lumbar spinal segment exists as a unit in which the intervertebral disc and facet joints function together to provide stability and assume stresses placed on the spine. In a biomechanical, cadaveric study, Adams and Hutton concluded that the function of the lumbar facet joints was to limit motion between vertebrae and protect the intervertebral discs from shear forces, excessive flexion, and axial rotation.[14] More recent biomechanical studies support the role of the lumbar facet joints as primary restraints to extension and axial torque and important secondary restraints to anterior and lateral shear as well as axial compression, particularly with high displacements of the spinal segment.[15,16] The lumbar facet joints assume approximately 15% of an axial compressive load, with the intervertebral disc assuming the remaining axial load.[17,34,35] Preserved disc height with a competent anterior anulus and anterior longitudinal ligament protects excessive loading of the facets in extension,[20,35] whereas loss of disc has been shown to significantly increase facet load.[17] A recent cadaveric biomechanical study of human lumbar spinal segments by Fujiwara *et al*[22] found a significant linear correlation between facet joint cartilage degeneration and intervertebral disc degeneration. Furthermore, Grade 3 facet cartilage degeneration (*i.e.*, cartilage incompletely covers the articular surfaces, with regions of exposed bone[28]) was associated with significantly increased axial rotation, lateral bending, flexion, and extension of the involved lumbar spine segments of males. Facet cartilage degeneration further increased the lumbar segmental movements that were already increased due to intervertebral disc degeneration.[22]

Although these biomechanical studies show that facet degeneration, along with intervertebral disc degeneration, leads to spinal segment instability, the association of the presence of facet fluid to radiographic lumbar instability has never previously been investigated before this study. Facet joint and intervertebral disc degeneration of a lumbar spinal segment leads to instability, which can be appreciated on weight-bearing flexion lateral lumbar radiographs as anterior subluxation.[5–7] When a patient with this condition lays supine (*e.g.*, during an MRI examination), the unstable lumbar spinal segment is unloaded and is therefore able to reduce posteriorly, producing a gap within the degenerated facet joint (Figure 5). Fluid that accumulates in this gap can be detected as a hyperintense signal on the T2-weighted MRI sequences.

In this study, instability was defined as the presence of anterior translation of L4 on L5 in the sagittal plane, as determined on the lateral flexion lumbar radiograph.

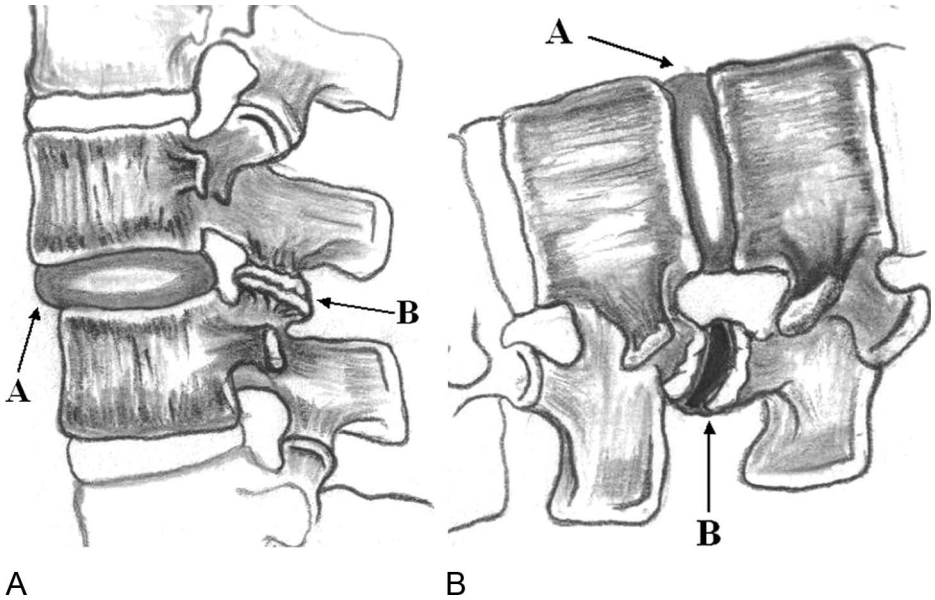


Figure 5. **A**, Schematic diagram of a degenerated lumbar spinal segment with spondylolisthesis in the upright position (**A** arrow). When the patient is upright, the degenerated facet joints (**B** arrow) are collapsed. **B**, Schematic diagram of the same degenerated lumbar spinal segment with the patient in a supine position. When the patient is supine, the spondylolisthesis (**A** arrow) reduces and a gap is created in the facet joints (**B** arrow). Fluid that fills this gap can be seen on MRI and should raise suspicion of dynamic lumbar instability.

This definition of instability does not take into account rotational or translational instability, which is not uncommon in patients with degenerative lumbar disease. It is quite possible that patients within this study had lumbar instability that was not detected on the flexion lumbar radiograph, but that would have been detected if other imaging methods, such as traction-compression radiographs,[9] dynamic MRI,[10–12] or three-dimensional dynamic computed tomography,[13] were used. The most reliable means of diagnosing lumbar segmental instability remains a matter of debate. Future prospective studies that evaluate the association between facet fluid and lumbar instability should include additional imaging techniques that may allow a more accurate diagnosis and quantification of lumbar instability. These imaging techniques are not commonly performed at our institution and were therefore not available for our review during this retrospective study. Plain AP and flexion radiographs and static MRI were used in this study because these are the imaging methods that are readily available in the clinical situation and are most commonly used in current clinical practice to evaluate the lumbar spine for degenerative disease and instability.

The results of this study support the published biomechanical and clinical imaging data that demonstrate an association between lumbar facet degeneration and spinal segmental instability.[17,22,34] This is the first study, to our knowledge, however, that demonstrates a clear association between lumbar facet fluid and segmental instability. It remains unanswered whether a segment with facet fluid on the MRI but no radiographic spondylolisthesis is at a higher risk of developing future instability. Also, if a segment that has facet fluid without dynamic instability is decompressed with a laminectomy without arthrodesis, is that level destined for iatrogenic instability? These questions remain unanswered and may be answered in the future with a careful prospective analysis.

## ■ Conclusion

The calculated facet fluid index correlated linearly with degree of instability noted on flexion lumbar radiographs, and the presence of facet fluid on the MRI had high positive predictive value for dynamic lumbar instability.

### ■ Key Points

- We found that a close linear association exists between lumbar facet fluid detected on MRI and radiographic instability detected on the flexion lumbar radiograph in patients with degenerative lumbar disease at L4–L5.
- The presence of facet fluid is indicative of radiographic lumbar instability with a relatively high positive predictive value (82%) and negative predictive value (83%).
- The presence of facet fluid on MRI should raise high suspicion of lumbar instability.

## References

1. Bridwell KH, Sedgewick TA, O'Brien MF, et al. The role of fusion and instrumentation in the treatment of degenerative spondylolisthesis with spinal stenosis. *J Spinal Disord* 1993;6:461–72.
2. Herkowitz HN, Kurz LT. Degenerative lumbar spondylolisthesis with spinal stenosis: a prospective study comparing decompression with decompression and intertransverse process arthrodesis. *J Bone Joint Surg Am* 1991;73:802–8.
3. Mardjetko SM, Connolly PJ, Shott S. Degenerative lumbar spondylolisthesis: a meta-analysis of literature 1970–1993. *Spine* 1994;19(suppl):2256–65.
4. Quinnell RC, Stockdale HR. Flexion and extension radiography of the lumbar spine: a comparison with lumbar discography. *Clin Radiol* 1983;34:405–11.
5. Boden SD, Wiesel SW. Lumbosacral segmental motion in normal individuals: have we been measuring instability properly? *Spine* 1990;15:571–6.
6. Bendo JA, Ong B. Importance of correlating static and dynamic imaging studies in diagnosing degenerative lumbar spondylolisthesis. *Am J Orthop* 2001;30:247–50.

7. Wood KB, Popp CA, Transfeldt EE, et al. Radiographic evaluation of instability in spondylolisthesis. *Spine* 1994;19:1697–703.
8. Stokes IA, Frymoyer JW. Segmental motion and instability. *Spine* 1987;12: 688–91.
9. Friberg O. Lumbar instability: a dynamic approach by traction-compression radiography. *Spine* 1987;12:119–29.
10. Vitzthum HE, Konig A, Seifert V. Dynamic examination of the lumbar spine by using vertical, open magnetic resonance imaging. *J Neurosurg* 2000; 93(suppl):58–64.
11. Haughton VM, Rogers B. Meyerand ME, et al. Measuring the axial rotation of lumbar vertebrae in vivo with MR imaging. *AJNR Am J Neuroradiol* 2002;23:1110–6.
12. Jinkins JR, Dworkin J. Proceedings of the State-of-the-Art Symposium on Diagnostic and Interventional Radiology of the Spine, Antwerp, September 7, 2002. Part 2. Upright, weight-bearing, dynamic-kinetic MRI of the spine: pMRI/kMRI. *JBR-BTR* 2003;86:286–93.
13. Ochia RS, Inoue N, Renner SM, et al. Three-dimensional in vivo measurement of lumbar spine segmental motion. *Spine* 2006;31:2073–8.
14. Adams MA, Hutton WC. The mechanical function of the lumbar apophyseal joints. *Spine* 1983;8:327–30.
15. Tencer AF, Mayer TG. Soft tissue strain and facet face interaction in the lumbar intervertebral joint: II. Calculated results and comparison with experimental data. *J Biomech Eng* 1983;105:210–5.
16. Tencer AF, Mayer TG. Soft tissue strain and facet face interaction in the lumbar intervertebral joint: I. Input data and computational technique. *J Biomech Eng* 1983;105:201–9.
17. Yang KH, King AI. Mechanism of facet load transmission as a hypothesis for low-back pain. *Spine* 1984;9:557–65.
18. el-Bohy AA, Yang KH, King AI. Experimental verification of facet load transmission by direct measurement of facet lamina contact pressure. *J Biomech* 1989;22:931–41.
19. Yamashita T, Minaki Y, Ozaktay AC, et al. A morphological study of the fibrous capsule of the human lumbar facet joint. *Spine* 1996;21:538–43.
20. Haher TR, O'Brien M, Dryer JW, et al. The role of the lumbar facet joints in spinal stability: identification of alternative paths of loading. *Spine* 1994;19: 2667–70 discussion 2671.
21. Fujiwara A, Tamai K, Yamato M, et al. The relationship between facet joint osteoarthritis and disc degeneration of the lumbar spine: an MRI study. *Eur Spine J* 1999;8:396–401.
22. Fujiwara A, Lim TH, An HS, et al. The effect of disc degeneration and facet joint osteoarthritis on the segmental flexibility of the lumbar spine. *Spine* 2000;25:3036–44.
23. Mailleux P, Ghosez JP, Bosschaert P, et al. Distension of the inter-facet joints in MRI and indirect sign of an existing underestimation of spondylolisthesis and canal stenosis. *J Belge Radiol* 1998;81:283–5.
24. Pevsner PH, Ondra S, Radcliff W, et al. Magnetic resonance imaging of the lumbar spine: a comparison with computed tomography and myelography. *Acta Radiol Suppl* 1986;369:706–7.
25. Modic MT, Steinberg PM, Ross JS, et al. Degenerative disk disease: assessment of changes in vertebral body marrow with MR imaging. *Radiology* 1988;166:193–9.
26. Murata M, Morio Y, Kuranobu K. Lumbar disc degeneration and segmental instability: a comparison of magnetic resonance images and plain radiographs of patients with low back pain. *Arch Orthop Trauma Surg* 1994;113: 297–301.
27. Bram J, Zanetti M, Min K, et al. MR abnormalities of the intervertebral disks and adjacent bone marrow as predictors of segmental instability of the lumbar spine. *Acta Radiol* 1998;39:18–23.
28. Grogan J, Nowicki BH, Schmidt TA, et al. Lumbar facet joint tropism does not accelerate degeneration of the facet joints. *AJNR Am J Neuroradiol* 1997;18:1325–9.
29. Grobler LJ, Robertson PA, Novotny JE, et al. Etiology of spondylolisthesis: assessment of the role played by lumbar facet joint morphology. *Spine* 1993; 18:80–91.
30. Boden SD, Riew KD, Yamaguchi K, et al. Orientation of the lumbar facet joints: association with degenerative disc disease. *J Bone Joint Surg Am* 1996;78:403–11.
31. Fujiwara, A, Tamai K, An HS, et al. Orientation and osteoarthritis of the lumbar facet joint. *Clin Orthop* 2001;385:88–94.
32. Dai LY. Orientation and tropism of lumbar facet joints in degenerative spondylolisthesis. *Int Orthop* 2001;25:40–2.
33. Rosner B. *Fundamentals of Biostatistics*, 5th ed. Belmont, CA: Duxbury Press; 1999:562–66.
34. Adams MA, Hutton WC. The effect of posture on the role of the apophysial joints in resisting intervertebral compressive forces. *J Bone Joint Surg Br* 1980;62:358–62.
35. Haher TR, Felmly WT, O'Brien M. Thoracic and lumbar fractures: diagnosis and management. In: Bridwell KH, Dewald RL, eds. *The Textbook of Spinal Surgery*. Philadelphia: Lippincott-Raven; 1997:1771–2.